



Italian Journal of Gynaecology & Obstetrics

March 2023 - Vol. 35 - N. 1 - Quarterly - ISSN 2385 - 0868

Surgical adhesions after laparoscopic myomectomy: methods of prevention

Paolo **Serafino**¹, Mario **Palumbo**^{1,*}, Francesco **Viciglione**¹, Antonio **Mercorio**¹, Valeria **Cafasso**¹, Dominga **Boccia**¹, Mario **Ascione**¹, Giuseppe **Bifulco**¹, Pierluigi **Giampaolino**², Luigi **Della Corte**²

¹Department of Public Health, School of Medicine, University of Naples Federico II, Naples, Italy.

²Department of Neuroscience, Reproductive Sciences and Dentistry, School of Medicine, University of Naples Federico II, Naples, Italy.

ARTICLE INFO

History

Received: 01 June 2022

Received in revised form: 31 July 2022

Accepted: 31 August 2022

Available online: 21 March 2023

DOI: 10.36129/jog.2022.56

Key words

Laparoscopic; myomectomy; adhesions; anti-adhesion agents; infertility.

*Corresponding author: Mario **Palumbo**, M.D. Department of Public Health, School of Medicine, University of Naples Federico II, via Sergio Pansini 5, 80131 Naples, Italy.
Email: mpalumbomed@gmail.com.
ORCID: 0000-0002-0670-2666.

ABSTRACT

Objective. Adhesions are one of the most common complications of myomectomy and subsequent surgical procedures. Laparoscopic myomectomy is a low-risk procedure, with an adhesion rate of 50%, unlike laparotomy which has increased rates of 94%. The primary consequences of postoperative adhesions are chronic pelvic pain and female infertility. This narrative review is conducted to report the evidence on methods to reduce adhesions after laparoscopic myomectomy.

Materials and Methods. An electronic database search (PubMed, Medline and Embase) was performed up to April 2022. A search algorithm was developed incorporating the terms “myomectomy”, “adhesions”, “laparoscopy”, “infertility”, “anti-adhesion agents”.

Results. The incidence of adhesions after laparoscopic myomectomy without adhesion barriers is variable, between 23% and 88%. The variability in adhesions' onset is due to tissue trauma, the incision location and length, number of knots or kind of suture material and the experience of the surgeon, but also the use of anti-adhesion agents. The icodextrin 4% and the auto-crosslinked hyaluronic acid solution gel showed a significant decrease in the incidence and severity of adhesions in intervention groups. The polyethylene glycol amine plus dextran aldehyde polymers reported a decrease in the total adhesion score at second-look surgery after laparoscopic myomectomy. Oxidized regenerated cellulose showed efficacy in prevention of adhesions after laparoscopic myomectomy.

Conclusions. Laparoscopic myomectomy reduces the risk of new adhesion formation but do not eliminate it entirely. Oxidized regenerated cellulose, auto-crosslinked hyaluronic acid gel among natural materials, and polyethylene glycol amine plus dextran aldehyde polymers among synthetic materials, decrease the incidence of adhesions.

INTRODUCTION

Adhesions are one of the most common complications of myomectomy that can affect woman's fertility and complicate subsequent surgical procedures, in fact in a study is reported that 55%-97% of women undergoing pelvic surgery form adhesions; several investigators indicated that adhesions after myomectomy by laparotomy occurred in all patients [1]. Laparoscopic myomectomy is a low-risk procedure, with an adhesion rate of 50%, unlike laparotomy which has increased rates of 94%. The mechanical stress suffered by the tissues in open surgery is greater and favours higher inflammatory and adhesion processes [2, 3].

Postoperative adhesions' formation is due to a fibrogenic process caused by different factors as tissue trauma, desiccation and hypoxia, such as peritoneum damage in myomectomy.

Peritoneal damage induces the activation of the inflammatory cascade and an excessive process degradation of fibrinogen to fibrin. Inflammation mediators, such as histamine and vasoactive kinins, mediate increased capillary permeability and cause outpouring of proteinaceous exudate. Fibrinous bands start from the denuded tissue arising from this exudate and connect different tissues in abnormal location. During peritoneal wound healing, mesothelial cells migrate from the underlying mesenchyme to reepithelialise the injured site. Fibrinolysis by plasmin can degrade these deposits, but, postoperatively, is typically inadequate. In fact, the hyperactivation of the fibrin deposition system compared to fibrinolysis lead to persistent fibrosis derived from fibroblasts activation and vascular invasion [4]. In abdominal and pelvic surgery peritoneal surface damage is ineluctable, but surgeon's skill and experience reduce the extent of this phenomenon. Adhesion's affection is correlated with the structures involved in this fibrotic process.

In the pelvis, clinical severity depends on the grade of involvement of ureters, bladder, rectosigmoid, uterus, fallopian tubes, ovaries, bowel loops, pelvic wall, nerves and blood vessels. The principal gynaecological consequences are chronic pelvic pain and female infertility. In fact, in 15% to 40% of infertile women presents pelvic adhesions [5]. Women infertility, due to tubal occlusion or endometrial's cavity distortion, is one of the most important indications for myomectomy. In addition, other indications are: abnormal uterine bleeding not responsive to pharmacological treatments

causing anaemia, pain or bulk-related symptoms that interferes with quality of life, growth after menopause and suspicious malignancy.

Postoperative adhesions formation is probably multifactorial: size, localization and number of myomas, blood loss, tissue traumatization grade, type of incision and suture, procedure length and utilization of anti-adhesion barriers.

The literature frequently wonders on what are the prevention methods and surgical techniques that are really effective in reduction of adhesions formation after laparoscopic myomectomy.

This review aimed to describe and evaluate the main prevention methods and techniques to reduce adhesions formation after laparoscopic myomectomy.

METHODS

An electronic database search (PubMed, Medline and Embase) was performed up to April 2022.

A search algorithm was developed incorporating the terms "myomectomy", "adhesions", "laparoscopy", "infertility", "oxidized regenerated cellulose", "auto-cross-linked hyaluronic acid gel", "polyethylene", "synthetic and natural materials", "anti-adhesion agents".

The analysis considers original studies evaluating the different surgical strategies available for the myomas' treatment and their association with adherence's formation.

Reproductive outcomes, medical signs and symptoms leading to the formation of adhesions were critically reviewed. Only articles in the English language were included.

Their reference lists were systematically reviewed to identify other studies for potential inclusion in this narrative review.

ADHESION CHARACTERISTICS

Surgical procedures can lead to pelvic adhesions in addition to pelvic inflammation and endometriosis. There is an important difference in the design and quality of studies relating to adhesions. There are two limits to study the incidence about pelvic adhesion postsurgical procedure, represented by heterogeneous anatomical and pathological pattern and the need of a second look laparotomy or laparoscopy. Concerning the second look, laparoscopy to lyse the adhesions must be considered only in selected cases because adhesions can reform in a high percentage of patients

after adhesiolysis. These cases are patients with adnexal adhesions that have unfavourable impact on fertility [6-8]. According to Okabayashi's review, the incidence of pelvic adhesions is around 51% (95%CI 40-63%) after obstetric and gynaecological surgery. In particular, the weighted mean adhesion formation is 41% (95%CI 29-53%) for caesarean section and 64% (95%CI 31-98%) for myomectomy [9]. In particular, the incidence of adhesions after laparoscopic myomectomy and without adhesion barriers is variable, between 23% and 88% [10]. Laparoscopy reduces the risk of new adhesion formation but do not eliminate it entirely. Patients undergoing open myomectomy developed adnexal adhesions more frequently than laparoscopic myomectomy (open 92% vs laparoscopic 13-65%). In addition, 35-53% of patients developed adhesions between the bowel and uterus [11, 12]. Despite the process of adhesions' formation starts early, the complications associated with adhesions occur directly after years between the initial surgery. A recent study shows that adhesions is the single most common cause of small-bowel obstruction in women [13]. Main complications with respect to the formation of adhesions are infertility, pregnancy disorders, development of dyspareunia, chronic abdominal and pelvic pain. Among the most frequent causes of chronic pelvic pain (CPP) there are the postoperative adhesions, excluding endometriosis, pelvic varices, interstitial cystitis and irritable bowel syndrome. In fact, adhesions are found in 25-50% of women with CPP. The intraperitoneal adhesions that are dense and vascular are more likely to induce pain when under traction and tension as a result of activation of nociceptors in the adhesion tissue and viscera. The stretching of peritoneum or visceral serosa at the adhesion's attachment sites is caused due to sexual intercourse or other physical activity such as running [14].

Laparoscopic myomectomy is often performed in women of childbearing age who want to preserve the uterus because they still have the desire of pregnancy [15]. Adhesions can be accountable for 20%-40% of female infertility due to an impaired interaction between the Fallopian tube and the ovary, in fact the adnexal adhesions could be responsible for fertility impairment [16, 17].

Fauconnier *et al.* [18] studied the prognostic factors for conception after laparoscopic myomectomy in 91 infertile patients, highlighting that the main factors involved are different, but the most incisive are the type of uterine suture, pathological compromises of the fallopian tubes and to end any pre-existing adhesions before myomectomy.

Furthermore, they found that the probability of conception after myomectomy was lower in the presence of a posterior myoma and/or an intramural myoma, situations that were recognized as risk factors for adhesions after myomectomy [18]. Another study [19] also supports the relationship between adhesions and an impaired fertility outcome. They studied the incidence of adhesions in laparoscopic myomectomy after the use of auto-crosslinked hyaluronic acid gel barriers and the use of two type of suture and pregnancy rate after 6 and 12 months. The pregnancy rate was significantly higher in the treatment group (44.2% after 6 months and 77.8% after 12 months, n = 18) than in the control group (22.2% after 6 months and 38.8% after 12 months, n = 18). Subserous sutures was also significantly associated with a higher pregnancy rate [17]. Other studies have shown that pre-existing adhesions can displace organs and anatomical structures, increasing the risk of involuntary intestinal, ureteral, [20] or vascular injury during surgical procedures [21].

ADHESIONS SCORE

In the literature there are different scores that are used to define the degree of adherence involvement. Most of the scores highlight the morphological characteristics of adhesions. In "The Operative Laparoscopy Study Group scoring system" adhesions are scored as follows: 0 – no adhesion; 1 – filmy and avascular; 2 – dense and/or vascular, and 3 – cohesive. The "American Fertility Society" modified score evaluates severity ("filmy" or "dense and vascular") and extent ("1/3", "1/3-2/3" or "2/3") of adhesions [22, 23].

Other Authors [24] have developed a novel clinical score for adhesion-related complications in abdominal and pelvic surgery: Clinical adhesion score (CLAS). This score includes outcomes and weight factors, describing the morbidity or clinical consequences of each adhesion-related complication: small bowel obstruction, difficulties at reoperation, female infertility, and chronic abdominal pain. The Clinical adhesion score includes factors that correct an adhesion score for the likelihood that symptoms are caused by adhesions. Symptoms of adhesion-related complications can be similar to symptoms of other conditions and there is some uncertainty about the clinical diagnosis of adhesions. The second-look surgery is considered

the gold standard for diagnosis of adhesions and with respect to use of this score it is possible to avoid reoperating to define a diagnosis.

ANTI-ADHESION METHODS AND TECHNIQUES IN LAPAROSCOPIC MYOMECTOMY

There are different ways to prevent adhesions formation in laparoscopic myomectomy (**Table 1**). Myomectomy is a surgery burdened by different adhesionogenic factors, such as high intrabdominal pressure, peritoneal irritations due to CO₂ effect, important blood loss, possible endometrium exposition, knots of the suture and tissue's traumatism and dehydration. First of all, it's possible to limit these factor evaluating the appropriate surgery indications, in fact every surgery involves adhesions formation. Furthermore, it's important to reduce surgery times and to operate with a reduced CO₂ pression, implying a reduction of interaction between CO₂ and abdominal tissues.

The most used technique to prevent adhesions formation is carrying out introflex suture, so as to avoid endometrium contact with other organ and peritoneal surfaces.

The damage to the underlying lining of the endometrium can cause intrauterine adhesions' formation.

The presence of these after myomectomy were previous uterine surgery (laparoscopic or laparotomy), the number of removed fibroids, the type and diameter of the largest myoma, and the opening of the uterine cavity. Diagnostic hysteroscopy, after 3 months from surgery, showed that opening of the uterine cavity and the laparotomic approach were independently associated with intrauterine adhesions, but further studies needed to confirm these potential effects [25].

The prevalence of intrauterine adhesions after myomectomy is low. In this study there is not significant difference in the occurrence of synechiae between the patients with and without uterine cavity breach [26].

There are not studies that support the use of anti-adherential agents after laparoscopic myomectomy for the low prevalence of intrauterine adhesions, but there are only studies after hysteroscopic myomectomy, as the use of crosslinked hyaluronic acid gels [27].

Given the negative impact of adhesions, in particular with respect to interventions such as myomectomy, severe endometriosis or adnexal pathologies, it is possible to decide to use anti-adhesion

Table 1. Adhesion-reduction tips.

Tips	
1.	Carefully handle tissue with field enhancement (magnification) techniques
2.	Perform diligent haemostasis but ensure diligent use of cautery Reduce cautery time and frequency and aspirate aerosolized tissue following cautery Reduce fulguration Reduce drying of tissues
3.	Use frequent irrigation and aspiration in laparoscopic surgery
4.	Reduce blood loss
5.	Reduce duration of surgery: Reduce pressure and duration of pneumoperitoneum
6.	Reduce risk of infection: maintain sterility and perform antibiotic prophylaxis
7.	Limit use of sutures and choose fine nonreactive sutures
8.	Prefer a subseros suture: introflex serosa
9.	Limit the number of nodes

agents, in fact some support routine application in all pelvic and abdominal surgeries. Scientific research still has much to do to demonstrate the real benefits of using these means and there is also insufficient evidence on the efficacy of anti-adhesion agents in the literature [28].

In the end, the use of endobag morcellation techniques is not associated with major complications or the greater association of adhesions, contained morcellation can be considered as a safe and unexpensive option [29], with a meticulous preoperative evaluation allowing a detailed accurate risk stratification before the surgery is mandatory for the negative impacts on the prognosis of an occult uterine malignancy morcellation [30].

THE SUTURE'S SECRETS

In a study evaluating the effectiveness of auto-crosslinked hyaluronic acid gel after laparoscopic myomectomy in infertile patients, it was shown that the rate of adhesions was significantly higher in patients treated with interrupted figure-8-like sutures than with subserous suture [31].

Actually, it is preferred to use an interrupted suture to guarantee a better mechanical resistance of the hysteroraphy, however, it's known the correlation between elevated number of knots and adhesions formation, for this reason it will be a good strategy to prefer a continue suture, but without affecting uterine's breach resistance.

A study investigated two different suture materials in a rat myomectomy model. The median mac-

roscopic adhesion score was significantly higher when a barbed suture material (polyglyconate) was used compared to the standard suture material (polyglactin-910) [32].

Another study about the incidence of postoperative adhesions after laparoscopic myomectomy with barbed suture indicated that the incidence of postoperative adhesion following the use of BS for wound closure in laparoscopic myomectomy was similar to that following the use of conventional suture [33].

BLEEDING'S CONTROL

Blood loss is directly proportional to adhesions formation, in fact a good operative strategy is characterized by a limited use of unipolar coagulator and preferring use of bipolar coagulator with a reduced bleeding, nevertheless an excessive cauterization of the tissue could improve the post-operative adhesions, and for this reason is better choosing tissue resection than tissue coagulation.

Finally, it is really important to irrigate and reabsorb frequently during the interventions to clean the site and reduce fibrotic process. Post-operative precautions are focused on infective risk preventions, because it is related with inflammatory process, that could lead to a release of inflammatory and profibrotic cytokines. All these methods are based on the recommendations of ESGE Adhesions research working group [34].

The blood loss is related with different factors such as myomas' size and number. The localization in this work [35] has not found impact on the amount of blood lost, but in another study intramural myomas with a size between 8 and 12 cm had a higher amount of blood loss compared to sub-serosal myomas of the same size (median blood loss = 275 vs 200, $p < 0.05$) [36].

Intramural and subserosal myomas were associated with an increased amount of blood loss if their size was > 12 cm [36]. Myomas > 6.5 cm were associated with a haemoglobin drop > 2 g/dl [37].

In addition, the impact of the number of myomas was also evaluated ≥ 5 myomas were found to be significantly associated with blood transfusion requirements within 1 week of the myomectomy, and there was a linear increase in blood loss with the size of myoma [38]. Hemoglobin drop of more than 2 units g/dl was found when there were ≥ 3 myomas [39].

NUMBER, SIZE AND LOCATION: THE BEST SURGICAL STRATEGY

Preoperative evaluation of the number, size and location of myomas in order to evaluate the surgical strategy to be adopted is very important because a crucial role for adhesion formation is the location and length of the incision. Indeed, incisions of the posterior uterus may be associated with a higher rate of adhesions, compared to anterior or fundal incisions, and tend to be more severe and dense and involve the adnexa more often (**Figure 1**). Several authors shown that adhesion formation was significantly higher in myomas located on the posterior wall (**Figure 2**) [40, 41]. Giampaolino *et al.* showed how women who underwent ovarian suspension had a significantly lower incidence of postoperative adhesion formation, particularly of moderate to severe adhesions.

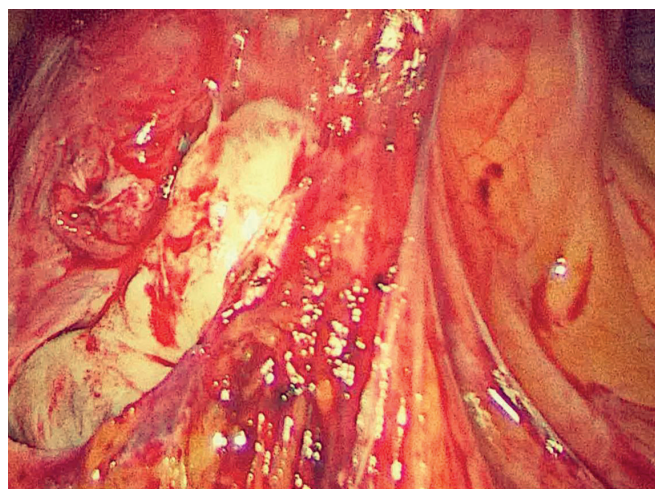


Figure 1. Recto-sigmoid adhesions with involvement of the left ovary and fallopian tube after laparoscopic myomectomy.

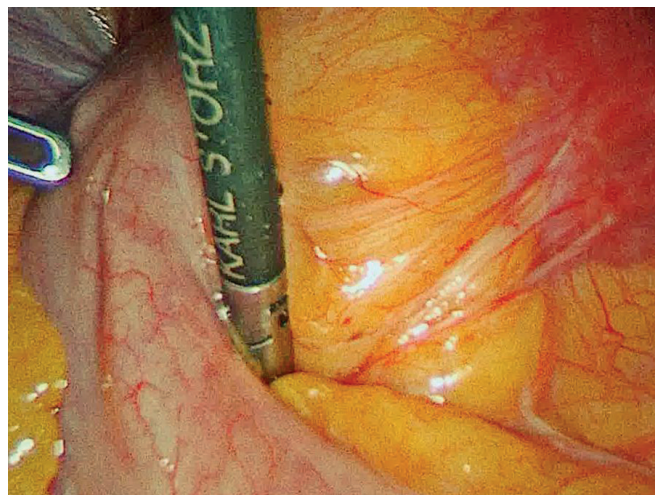


Figure 2. Recto-sigmoid adhesions and posterior uterine wall after laparoscopic myomectomy.

Ovarian suspension may reduce the rate and severity of postoperative adhesions formation in women undergoing laparoscopy [42].

Dubuisson *et al.* found that adhesions were present in 33.3% of the patients after a posterior incision, while adhesions developed in only 4.8% of the patients after an anterior or fundal incision [43].

The length of the incision must be proportional to the size of the myoma and in case of multiple myomas it is preferable to perform a single incision because it has been calculated that every additional centimetre of incision length, the total adhesion area over the uterine serosal surface increased by 0.55 cm² [44].

ANTI-ADHESION AGENTS: PHARMACOLOGICAL AND NONPHARMACOLOGICAL AGENTS

Despite the surgeon performs the technique correctly following all the recommendations for adhesions reduction, these are formed regardless because the formation of adhesions is a complication of any surgery, not only laparoscopic myomectomy. There are pharmacological and nonpharmacological agents designed to limit this complication.

Currently, no pharmacological agent has been shown to prevent the development of adhesion in humans, but only patients who received steroids were less likely to have a worsening adhesion score [45, 46]. In this work we have decided to focus only on products that have shown results.

Nonpharmacological agents function by separating injured tissues over a certain time period, these are divided into fluid and barrier agents. Fluid agents include icodextrin, hyaluronic acid and synthetic hydrogel. Barrier agents include sodium hyaluronate-carboxymethylcellulose (HA-CMC), oxidized regenerated cellulose (ORC), and the use of synthetic materials.

FLUID AGENTS

Firstly, 4% icodextrin solution, a high-molecular-weight polymer solution, has been proposed for intraoperative irrigation after several pelvic surgical procedures, showing some evidences of effectiveness [47, 48]. Ninety-one patients were randomized to have icodextrin 4% solution administered intraperitoneally: the adhesion severity

score seems lower in the group treated with the addition of icodextrin [47].

Auto-crosslinked polymer gels of hyaluronic acid (HA) are biocompatible hydrogels that exhibit improved viscoelastic properties and prolonged *in vivo* residence times compared to the native polymer. This crosslinking is achieved through a base-catalysed reaction consisting of the activation of HA carboxyl groups by 2-chloro-1-methylpyridinium iodide (CMPI) and after nucleophilic acyl substitution by the hydroxyl groups of HA in organic solvent. Mais *et al.* assessed the efficacy of auto-crosslinked HA gel. This study, instead, found significant decrease when the uterine score was corrected for the baseline adhesions status of the patients ($p = 0.03$) but there were not significant differences even in total and uterine adhesion scores [49].

In this different paper is detected a significant decrease in the incidence of adhesions in the intervention group such decrease (relative risk = 0.64; $p = 0.17$) [50].

SYNTHETIC MATERIALS

The use of a synthetic materials, polyethylene glycol amine plus dextran aldehyde polymers reported a statistically significant decrease in the total score at second-look surgery after laparoscopic myomectomy between the treatment and the control group, in a study to investigate the anti-adhesive efficacy. If considering all the operated sites throughout the abdominal cavity, there is a statistically significant reduction in adhesion score for intervention patients compared with controls ($p < 0.01$) [51-53].

ADHESION BARRIER

A further adhesion barrier is the sodium hyaluronate-carboxymethylcellulose (HA-CMC) that increases HA half-life and its effect on the scarified surface are prolonged, providing a long-lasting anti-adhesive barrier. Fossum *et al.* reported that the application of a modified HA and CMC powder after laparoscopic myomectomy did not demonstrate any difference in the incidence of adhesions between the intervention and the control groups [48]. The barrier agents with the greatest results in laparoscopic myomectomy is oxidized regenerated cellulose (ORC) that increases the tissue plasmino-

gen activator (tPA)/plasminogen activator inhibitor (PAI 1) ratio in fibroblasts isolated from the adhesion tissues [54] and reduces the inflammatory response by acting on macrophages, another potential mechanism to decrease adhesion formation [55, 56]. US Food and Drug Administration approved the ORC as the first anti-adhesion product, which showed a good effect in animal models, besides an extreme biocompatibility [57-59]. *In vivo*, in gynaecological and general surgery, in laparoscopy and in laparotomy, ORC was proven a reduction in the formation of adhesions [60]. The ORC membrane should not be applied to bleeding surfaces, because the presence of blood risks to impair its effectiveness.

Two studies assessed the efficacy of ORC in the prevention of adhesions after laparoscopic myomectomy [61, 62]. The incidence of adhesions at second-look surgery was significantly lower in the intervention group compared to the control group in one study ($p < 0.05$). When considered the total adhesion score at the second-look surgery, the difference was significant in both trials ($p = 0.0026$ and $p = 0.0021$) [63].

Oxidized regenerated cellulose (ORC) adhesion barrier showed a significant decrease in the uterine adhesion score in the intervention group only for a posterior localization of myomas ($p = 0.007$) and when considering an anterior localization of myomas were not significant decrement the incidence of *de novo* adhesions (odds ratio = 1.11; $p = 0.693$), in the total adhesion score and in the uterine score [64-67].

CONCLUSIONS

Adhesion development after laparoscopic myomectomy is a common problem every surgeon. Several factors induce development of adhesion such as desiccation or inappropriate tissue handling but also number of previous surgeries, surgical technique, and the predisposition of individual patients. In laparoscopic myomectomy, the incision location and length, number of knots, or kind of suture material, and use of adhesion barrier can help to reduce the incidence of adhesions and the decrease adhesion-associated complications. The myomectomy is often performed to preserve or restore childbearing potential, as long as a strategies of adhesion prevention should be used. In fact, besides a careful tissue handling, the use of an anti-adhesion agent can be a successful strategy.

Limitations and biases of the studies are including the lack of a second-look surgery and a loss of follow-up for patients who did not undergo a subsequent surgery. Despite the data are controversial, the barriers methods that seemed to show the most promising results in reducing the incidence of adhesions after laparoscopic myomectomy were ORC and the auto-crosslinked HA gel among natural materials, and polyethylene glycol amine plus dextran aldehyde polymers among synthetic materials. It would be interesting to investigate adhesion barriers possible efficacy on long term outcomes, such as infertility, small bowel obstruction, and chronic abdominopelvic pain, that was not evidenced.

COMPLIANCE WITH ETHICAL STANDARDS

Author contributions

P.S., M.P.: Conceptualization. P.S., M.P., F.V., V.C., D.B., M.A.: Data curation. P.S., M.P.: Project administration. P.S., M.P., F.V., A.M.: Writing – original draft. P.S., M.P., F.V., A.M.: Writing – review & editing. P.S., M.P., P.G., G.B., L.D.C.: Investigation. P.G., G.B., L.D.C.: Supervision, validation,

Funding

None.

Study registration

N/A.

Disclosure of interests

The authors declare that they have no conflict of interests.

Ethical approval

N/A.

Informed consent

N/A.

Data sharing

N/A.

REFERENCES

1. Tsuji S, Takahashi K, Yomo H, Fujiwara M, Kita N, Takebayashi K, et al. Effectiveness of antiadhesion barriers in preventing adhesion after myomectomy in patients with uterine leiomyoma. *Eur J Obstet Gynecol Reprod Biol.* 2005;123(2):224-48. doi: 10.1016/j.ejogrb.2005.04.012.
2. Seracchioli R, Venturoli S, Colombo FM, Bagnoli A, Vianello F, Govoni F, et al. GnRH agonist treatment before total laparoscopic hysterectomy for large uteri. *J Am Assoc Gynecol Laparosc.* 2003;10(3):316-9. doi: 10.1016/s1074-3804(05)60254-x.
3. Della Corte L, Mercurio A, Morra I, Riemma G, De Franciscis P, Palumbo M, et al. Spinal Anesthesia versus General Anesthesia in Gynecological Laparoscopic Surgery: A Systematic Review and Meta-Analysis. *Gynecol Obstet Invest.* 2022;87(1):1-11. doi: 10.1159/000521364.
4. Diamond MP, Freeman ML. Clinical implications of postsurgical adhesions. *Hum Reprod.* 2001;7(2):567-76. doi: 10.1093/humupd/7.6.567.
5. Di Donato N, Montanari G, Benfenati A, Monti G, Bertoldo V, Mauloni M, et al. Do women with endometriosis have to worry about sex? *Eur J Obstet Gynecol Reprod Biol.* 2014;179:69-74. doi: 10.1016/j.ejogrb.2014.05.022.
6. Vrijland WW, Jeekel J, van Geldorp HJ, Swank DJ, Bonjer HJ. Abdominal adhesions: intestinal obstruction, pain, and infertility. *Surg Endosc.* 2003;17(7):1017-22. doi: 10.1007/s00464-002-9208-9.
7. Zerega GS, Verco SJ, Young P, Kettel M, Kobak W, Martin D, et al. A randomized, controlled pilot study of the safety and efficacy of 4% icodextrin solution in the reduction of adhesions following laparoscopic gynaecological surgery. *Hum Reprod.* 2002;17(4):1031-8. doi: 10.1093/humrep/17.4.1031.
8. Swank DJ, Hop WC, Jeekel J. Reduction, regrowth, and de novo formation of abdominal adhesions after laparoscopic adhesiolysis: a prospective analysis. *Dig Surg.* 2004;21(1):66-71. doi: 10.1159/000076023.
9. Okabayashi K, Ashrafian H, Zacharakis E, Hasegawa H, Kitagawa Y, Athanasiou T, et al. Adhesions after abdominal surgery: a systematic review of the incidence, distribution and severity. *Surg Today.* 2014;44(3):405-20. doi: 10.1007/s00595-013-0591-8.
10. Herrmann A, Torres-de la Roche LA, Krentel H, Cezar C, de Wilde MS, Devassy R, et al. Adhesions after Laparoscopic Myomectomy: Incidence, Risk Factors, Complications, and Prevention. *Gynecol Minim Invasive Ther.* 2020;9(4):190-7. doi: 10.4103/GMIT.GMIT_87_20.
11. Assaf A. Adhesions after laparoscopic myomectomy: effect of the technique used. *Gynaecol Endosc.* 1999;8:225-9. doi: 10.1046/j.1365-2508.1999.00246.x.
12. Takeuchi H, Kitade M, Kikuchi I, Shimanuki H, Kumakiri J, Kinoshita K. Adhesion-prevention effects of fibrin sealants after laparoscopic myomectomy as determined by second-look laparoscopy: a prospective, randomized, controlled study. *J Reprod Med.* 2005;50(8):571-7. Available at: <https://pubmed.ncbi.nlm.nih.gov/16220761/>.
13. ten Broek RP, Issa Y, van Santbrink EJ, Bouvy ND, Kruitwagen RF, Jeekel J, et al. Burden of adhesions in abdominal and pelvic surgery: systematic review and met-analysis. *BMJ.* 2013;347:f5588. doi: 10.1136/bmj.f5588.
14. Vercellini P, Somigliana E, Viganò P, Abbiati A, Barbara G, Fedele L. Chronic pelvic pain in women: etiology, pathogenesis and diagnostic approach. *Gynecol Endocrinol.* 2009;25(3):149-58. doi: 10.1080/09513590802549858.
15. Della Corte L, Fabozzi A, Morra I, Bifulco G, Giampaolino P. Disseminated peritoneal leiomyomatosis 10 years after a laparoscopic myomectomy: A brief communication. *Eur J Obstet Gynecol Reprod Biol.* 2018;224:58-9. doi: 10.1016/j.ejogrb.2018.03.016.
16. Diamond MP, Freeman ML. Clinical implications of postsurgical adhesions. *Hum Reprod Update.* 2001;7(6):567-76. doi: 10.1093/humupd/7.6.567.
17. Trew G. Postoperative adhesions and their prevention. *Rev Gynaecol Perinatal Pract.* 2006;6(1-2):47-56. doi: 10.1016/j.rigapp.2006.02.001.
18. Fauconnier A, Dubuisson JB, Ancel PY, Chapron C. Prognostic factors of reproductive outcome after myomectomy in infertile patients. *Hum Reprod.* 2000;15(8):1751-7. doi: 10.1093/humrep/15.8.1751.
19. Pellicano M, Guida M, Bramante S, Acunzo G, Di Spiezio Sardo A, et al. Reproductive outcome after autocrosslinked hyaluronic acid gel application in infertile patients who underwent laparoscopic myomectomy. *Fertil Steril.* 2005;83(2):498-500. doi: 10.1016/j.fertnstert.2004.09.019.
20. Kumakiri J, Kikuchi I, Kitade M, Kuroda K, Matsuoka S, Tokita S, et al. Incidence of com-

- plications during gynecologic laparoscopic surgery in patients after previous laparotomy. *J Minim Invasive Gynecol.* 2010;17(4):480-6. doi: 10.1016/j.jmig.2010.03.004.
21. Herrmann A, De Wilde RL. Adhesions are the major cause of complications in operative gynecology. *Best Pract Res Clin Obstet Gynaecol.* 2016;35:71-83. doi: 10.1016/j.bpobgyn.2015.10.010.
 22. Operative Laparoscopy Study Group. Postoperative adhesion development after operative laparoscopy: evaluation at early second-look procedures. *Operative Laparoscopy Study Group. Fertil Steril.* 1991;55(4):700-4. doi: 10.1016/S0015-0282(16)54233-2.
 23. The American Fertility Society. The American Fertility Society classifications of adnexal adhesions, distal tubal occlusion, tubal occlusion secondary to tubal ligation, tubal pregnancies, müllerian anomalies and intrauterine adhesions. *Fertil Steril.* 1988;49(6):944-55. doi: 10.1016/s0015-0282(16)59942-7.
 24. Lier EJ, van den Beukel BAW, Gawria L, van der Wees PJ, van den Hil L, Bouvy ND, et al. Clinical adhesion score (CLAS): development of a novel clinical score for adhesion-related complications in abdominal and pelvic surgery. *Surg Endosc.* 2021;35(5):2159-68. doi: 10.1007/s00464-020-07621-5.
 25. Laganà AS, Garzon S, Dababou S, Uccella S, Medvediev M, Pokrovenko D, et al. Prevalence of Intrauterine Adhesions after Myomectomy: A Prospective Multicenter Observational Study. *Gynecol Obstet Invest.* 2022;87(1):62-9. doi: 10.1159/000522583.
 26. Boudova B, Hlinecka K, Lisa Z, Richtarova A, Zizka Z, Mara M. Hysteroscopic findings after laparoscopic and open myomectomy with or without uterine cavity breach: historical cohort study. *Minim Invasive Ther Allied Technol.* 2022;31(5):789-96. doi: 10.1080/13645706.2021.1986542.
 27. Huang CY, Chang WH, Cheng M, Huang HY, Horng HC, Chen YJ, et al. Crosslinked Hyaluronic Acid Gels for the Prevention of Intrauterine Adhesions after a Hysteroscopic Myomectomy in Women with Submucosal Myomas: A Prospective, Randomized, Controlled Trial. *Life (Basel).* 2020;10(5):67. doi: 10.3390/life10050067.
 28. Practice Committee of the American Society for Reproductive Medicine in collaboration with the Society of Reproductive Surgeons. Practice Committee of the American Society for Reproductive Medicine. Postoperative adhesions in gynecologic surgery: a committee opinion. *Fertil Steril.* 2019;112(3):458-63. doi: 10.1016/j.fertnstert.2019.06.027.
 29. Feghali EJ, Laganà AS, Daccache A, Bitar R, Garzon S, Uccella S, et al. Endobag use in laparoscopic gynecological surgeries: a systematic review. *Minim Invasive Ther Allied Technol.* 2022;31(5):698-703. doi: 10.1080/13645706.2021.1982727.
 30. Mercurio A, Della Corte L, Vetrella M, Russo M, Serafino P, Palumbo M, et al. Uterine fibroids morcellation: a puzzle topic. *Minim Invasive Ther Allied Technol.* 2022;31(7):1008-16. doi: 10.1080/13645706.2022.2095872.
 31. Pellicano M, Bramante S, Cirillo D, Palomba S, Bifulco G, Zullo F, et al. Effectiveness of autocrosslinked hyaluronic acid gel after laparoscopic myomectomy in infertile patients: a prospective, randomized, controlled study. *Fertil Steril.* 2003;80(2):441-4. doi: 10.1016/s0015-0282(03)00597-1.
 32. Api M, Boza A, Cıkman MS, Aker FV, Onenerk M. Comparison of barbed and conventional sutures in adhesion formation and histological features in a rat myomectomy model: randomized single blind controlled trial. *Eur J Obstet Gynecol Reprod Biol.* 2015;185:121-5. doi: 10.1016/j.ejogrb.2014.11.032.
 33. Kumakiri J, Kikuchi I, Kitade M, Ozaki R, Kawasaki Y. Incidence of Postoperative Adhesions after Laparoscopic Myomectomy with Barbed Suture. *Gynecol Obstet Invest.* 2020;85(4):336-42. doi: 10.1159/000510511.
 34. De Wilde RL, Bakkum EA, Brölmann H, Crowe A, Koninckx P, Korell M, et al. Consensus recommendations on adhesions (version 2014) for the ESGE Adhesions Research Working Group (European Society for Gynecological Endoscopy): an expert opinion. *Arch Gynecol Obstet.* 2014;290(3):581-2. doi: 10.1007/s00404-014-3312-7.
 35. Watrowski R, Jäger C, Forster J. Predictors of postoperative hemoglobin drop after laparoscopic myomectomy. *Wideochir Inne Tech Maloinwazyjne.* 2017;12(1):81-7. doi: 10.5114/wiitm.2017.66515.
 36. Saccardi C, Gizzo S, Noventa M, Ancona E, Borghero A, Litta, PS. Limits and complications of laparoscopic myomectomy: which are the best predictors? A large cohort single-center experience. *Arch Gynecol Obstet.* 2014;290(5):951-6. doi: 10.1007/s00404-014-3289-2.
 37. Cho H. Prediction of Postoperative Anemia Following Laparoscopic Myomectomy. *Gynecol*

- Surgery Conference 20th Annu Congr ESGE. 2011. United Kingdom Conference Publication, London 2011, pp. S159-60.
38. Sleiman Z, Baba RE, Garzon S, Khazaka A. The Significant Risk Factors of Intra-Operative Hemorrhage during Laparoscopic Myomectomy: A Systematic Review. *Gynecol Minim Invasive Ther.* 2019;9(1):6-12. doi: 10.4103/GMIT.GMIT_21_19.
 39. Rock WA Jr, Meeks GR. Managing anemia and blood loss in elective gynecologic surgery patients. *J Reprod Med.* 2001;46(5 Suppl):507-14. Available at: <https://pubmed.ncbi.nlm.nih.gov/11396384/>.
 40. Takeuchi H, Kinoshita K. Evaluation of adhesion formation after laparoscopic myomectomy by systematic second-look microlaparoscopy. *J Am Assoc Gynecol Laparosc.* 2002;9(4):442-6. doi: 10.1016/s1074-3804(05)60516-6.
 41. Keckstein J, Karageorgieva E, Darwish A, Grab D, Paulus W, Tuttlies F. Laparoscopic Myomectomy: Sonographic Follow-Up and Second-Look Laparoscopy for the Evaluation of a New Technique. *J Am Assoc Gynecol Laparosc.* 1994;1(4, Part 2):S16. doi: 10.1016/s1074-3804(05)80920-x.
 42. Giampaolino P, Della Corte L, Saccone G, Vitaliano A, Bifulco G, Calagna G, et al. Role of Ovarian Suspension in Preventing Postsurgical Ovarian Adhesions in Patients with Stage III-IV Pelvic Endometriosis: A Systematic Review. *J Minim Invasive Gynecol.* 2019;26(1):53-62. doi: 10.1016/j.jmig.2018.07.021.
 43. Dubuisson JB, Fauconnier A, Chapron C, Kreiker G, Nørgaard C. Second look after laparoscopic myomectomy. *Hum Reprod.* 1998;13(8):2102-6. doi: 10.1093/humrep/13.8.2102.
 44. Coddington CC, Grow DR, Ahmed MS, Toner JP, Cook E, Diamond MP. Gonadotropin-releasing hormone agonist pretreatment did not decrease postoperative adhesion formation after abdominal myomectomy in a randomized control trial. *Fertil Steril.* 2009;91(5):1909-13. doi: 10.1016/j.fertnstert.2008.02.128.
 45. Carlson NS. From Cochrane Database of Systematic Reviews (CDSR) Issue 2-4, 2016. *J Midwifery Womens Health.* 2016;61:513-5. doi: 10.1111/jmwh.12501_2.
 46. Ahmad G, Mackie FL, Iles DA, O'Flynn H, Dias S, Metwally M, et al. Fluid and pharmacological agents for adhesion prevention after gynaecological surgery. *Cochrane Database Syst Rev.* 2014;(7):CD001298. doi: 10.1002/14651858.CD001298.pub4.
 47. Catena F, Ansaloni L, Di Saverio S, Pinna AD. On Behalf of the World Society of Emergency Surgery. P.O.P.A. Study: Prevention of Postoperative Abdominal Adhesions by Icodextrin 4% Solution After Laparotomy for Adhesive Small Bowel Obstruction. A Prospective Randomized Controlled Trial. *J Gastrointest Surg.* 2012;16(2):382-8. doi: 10.1007/s11605-011-1736-y.
 48. Fossum GT, Silverberg KM, Miller CE, Diamond MP, Holmdahl L. Gynecologic use of Sepraspay Adhesion Barrier for reduction of adhesion development after laparoscopic myomectomy: a pilot study. *Fertil Steril.* 2011;96(2):487-91. doi: 10.1016/j.fertnstert.2011.05.081.
 49. Mais V, Bracco GL, Litta P, Gargiulo T, Melis GB. Reduction of postoperative adhesions with an auto-crosslinked hyaluronan gel in gynaecological laparoscopic surgery: a blinded, controlled, randomized, multicentre study. *Hum Reprod.* 2006;21(5):1248-54. doi: 10.1093/humrep/dei488.
 50. Pellicano M, Bramante S, Cirillo D, Palomba S, Bifulco G, Zullo F, et al. Effectiveness of autocrosslinked hyaluronic acid gel after laparoscopic myomectomy in infertile patients: a prospective, randomized, controlled study. *Fertil Steril.* 2003;80(2):441-4. doi: 10.1016/s0015-0282(03)00597-1.
 51. Tinelli A, Malvasi A, Guido M, Tsin DA, Hudelist G, Hurst B, et al. Adhesion formation after intracapsular myomectomy with or without adhesion barrier. *Fertil Steril.* 2011;95(5):1780-5. doi: 10.1016/j.fertnstert.2010.12.049.
 52. Trew GH, Pistofidis GA, Brucker SY, Krämer B, Ziegler NM, Korell M, et al. A first-in-human, randomized, controlled, subject- and reviewer-blinded multicenter study of Actamax™ Adhesion Barrier. *Arch Gynecol Obstet.* 2017;295(2):383-95. doi: 10.1007/s00404-016-4211-x.
 53. Liu S, Hu C, Li F, Li XJ, Cui W, Fan C. Prevention of peritendinous adhesions with electrospun ibuprofen-loaded poly(L-lactic acid)-polyethylene glycol fibrous membranes. *Tissue Eng Part A.* 2013;19(3-4):529-37. doi: 10.1089/ten.TEA.2012.0208.
 54. Gago LA, Saed G, Elhammady E, Diamond MP. Effect of oxidized regenerated cellulose (Interceed) on the expression of tissue plasminogen activator and plasminogen activator inhibitor-1 in human peritoneal fibroblasts and mesothelial cells. *Fertil Steril.* 2006;86(Suppl 4):1223-7. doi: 10.1016/j.fertnstert.2006.04.021.
 55. Reddy S, Santanam N, Reddy PP, Rock JA, Murphy AA, Parthasarathy S. Interaction of Interceed oxidized regenerated cellulose with

- macrophages: a potential mechanism by which Interceed may prevent adhesions. *Am J Obstet Gynecol.* 1997;177(6):1315-20; discussion 1320-1. doi: 10.1016/s0002-9378(97)70070-x.
56. Puente Gonzalo E, Alonso Pacheco L, Vega Jiménez A, Vitale SG, Raffone A, Laganà AS. Intrauterine infusion of platelet-rich plasma for severe Asherman syndrome: a cutting-edge approach. *Updates Surg.* 2021;73(6):2355-62. doi: 10.1007/s13304-020-00828-0.
 57. Laganà AS, Ciancimino L, Mancuso A, Chiofalo B, Rizzo P, Triolo O. 3D sonohysterography vs hysteroscopy: a cross-sectional study for the evaluation of endouterine diseases. *Arch Gynecol Obstet.* 2014;290(6):1173-8. doi: 10.1007/s00404-014-3366-6.
 58. Alkatout I, Mechler U, Mettler L, Pape J, Maass N, Biebl M, et al. The Development of Laparoscopy-A Historical Overview. *Front Surg.* 2021;8:799442. doi: 10.3389/fsurg.2021.799442.
 59. Park H, Baek S, Kang H, Lee D. Biomaterials to Prevent Post-Operative Adhesion. *Materials (Basel).* 2020;13(14):3056. doi: 10.3390/ma13143056.
 60. Laganà AS, Garzon S, D'Alterio MN, Noventa M, Stabile G, Naem A, et al. Mini-Laparoscopy or Single-Site Robotic Surgery in Gynecology? Let's Think out of the Box. *J Invest Surg.* 2022;35(2):440-1. doi: 10.1080/08941939.2020.1857480.
 61. Ahmad G, O'Flynn H, Hindocha A, Watson A. Barrier agents for adhesion prevention after gynaecological surgery. *Cochrane Database Syst Rev.* 2015;(4):CD000475. doi: 10.1002/14651858.CD000475.pub3.
 62. Reid RL, Hahn PM, Spence JE, Tulandi T, Yuzpe AA, Wiseman DM. A randomized clinical trial of oxidized regenerated cellulose adhesion barrier (Interceed, TC7) alone or in combination with heparin. *Fertil Steril.* 1997;67(1):23-9. doi: 10.1016/s0015-0282(97)81850-x.
 63. Pal B. Adhesion prevention in myomectomy. *J Gynecol Endosc Surg.* 2011;2(1):21-4. doi: 10.4103/0974-1216.85275.
 64. Mais V, Ajossa S, Piras B, Guerriero S, Marongiu D, Melis GB. Prevention of de-novo adhesion formation after laparoscopic myomectomy: a randomized trial to evaluate the effectiveness of an oxidized regenerated cellulose absorbable barrier. *Hum Reprod.* 1995;10(12):3133-5. doi: 10.1093/oxfordjournals.humrep.a135873.
 65. Moufawad G, Buzzaccarini G, Abboud K, Nasr E, Geru M, Sleiman Z. Cervicovaginal fibroids: a systematic review for a comprehensive management plan. *Ital J Gynaecol Obstet.* Ahead of print. doi: 10.36129/jog.2022.41.
 66. Sleiman A, Ayed A, Christoforou C, Petousis S, Alkatout I, Gitas G, et al. Posterior cervico-vaginal myomectomy: a laparoscopic technique. *Ital J Gynaecol Obstet.* 2023;35(1):21-5. doi: 10.36129/jog.2022.36.
 67. Han ES, Scheib SA, Patzkowsky KE, Simpson K, Wang KC. The sticky business of adhesion prevention in minimally invasive gynecologic surgery. *Curr Opin Obstet Gynecol.* 2017;29(4):266-75. doi: 10.1097/GCO.0000000000000372.