

Minimally Invasive Approaches to Optimize Block Grafting: A Case Report

Gilberto Sammartino, MD, DDS^{1*}
Giuseppe Pantaleo, DDS¹
Paolo Nuzzolo, DDS¹
Massimo Amato, MD, DDS²
Francesco Riccitiello, MD, DDS¹

INTRODUCTION

Anarrow alveolar ridge is a challenging situation that surgeons may face when considering implant oral rehabilitation. Many surgical approaches exist, and the most frequently used is bone grafting.¹

The subperiosteal tunneling approach is a minimally invasive procedure that allows the surgeon to allocate the graft in a space that is obtained between the soft tissues and the underlying bone through an access represented by a single incision on the mesial limit of the bone defect.^{2,3} This approach ensures minimal discomfort for the patient after the surgery and mostly steady coverage of the graft during the healing time, with minimal risk of exposure, infection, and failure.^{4,5} The subperiosteal tunneling technique uses autologous bone, which is still considered the gold standard for bone regeneration.⁶

On the other hand, autologous bone grafting requires donor-site surgery, which often means donor-site surgery complications, especially when larger amounts of bone are needed and extraoral sites are accessed for the harvest. Moreover, they need general anesthesia.^{7,8}

Homologous grafting refers to the use of bone from living donors of the same species or from cadavers. The bone is processed and stored in tissue banks. Depending on the type of treatment, fresh frozen bone (FFB), freeze-dried bone, and demineralized freeze-dried bone can be obtained.^{4,9,10}

The case presented here combines the tunnel flap technique and the use of homologous bone to achieve the least invasive approach to bilateral block grafting of an upper maxillary affected by severe horizontal bone atrophy in order to allow a full-arch implant rehabilitation.

CASE PRESENTATION

A 55-year-old white woman was referred to the Dental School of the University Federico II of Naples. No significant clinical

data (diabetes, hypertension, allergies) were present in her clinical history; laboratory results were substantially normal.

The patient was partially edentulous and showed severe horizontal bone atrophy in the maxillary arch. The only teeth in the arch were the canines and the second molars, which had already been treated.

Because of the periodontal and endodontic condition of the remaining teeth, implant therapy and a full arch prosthetic restoration were chosen for the patient. Horizontal bone augmentation was necessary, as the ridge showed no sufficient horizontal dimensions for the placement of implants in the right and left posterior sectors, and block grafting was a mandatory option because of the degree of atrophy and the noncontentive anatomy of the defect. There was no need for an additional vertical augmentation (Figures 1 and 2).

A minimally invasive approach was chosen for the exposure of the receiving sites. Instead of creating a traditional flap, a mucoperiosteal tunnel was created with a periosteal elevator through a single incision of moderate dimensions per hemiarch on the mesial edge of each of the defects (right and left) from the occlusal to the apical limit of the ridge on its vestibular side (Figure 3).

Tissue bank ilium bicortical bone (FFB) was chosen for the grafting material. After being defrosted in sterile saline solution, each block was split, obtaining cortical bone on one side and trabecular bone on the other. The cortical bone was to be positioned on the interface with the soft tissue, and the trabecular bone was to be placed on the interface with the host site (Figure 4). The host site had already been drilled to facilitate bleeding, start the regional acceleratory process, and expose trabecular bone.

Three microscrews fixed on the mesial side of the graft allowed the complete fixation of the block, avoiding any movement or tilting (Figure 5). Platelet-rich fibrin (PRF) was then placed on the graft.

Besides the block grafting on the right and left posterior regions, a flap was elevated in the frontal region, which showed good bone quality, quantity, and anatomy; two 4 × 11.5 mm submerged tapered implants were placed (Figure 6). Polygalactin 910 (Coated Vicryl, Ethicon, Somerville, NJ 4/0 resorbable sutures were used for flaps closure.

The 4 remaining teeth were not extracted at this phase so they could be used to support a fixed provisional prosthesis (Figure 7). The patient was scheduled for regular follow-ups for the next 5 months.

¹ Department of Neurosciences, Reproductive and Odontostomatological Sciences, University of Naples Federico II, Naples, Italy.

² Department of Medicine and Surgery, University of Salerno, Salerno, Italy.

* Corresponding author, e-mail: gilberto.sammartino@unina.it

DOI: 10.1563/aaid-joi-D-14-00076

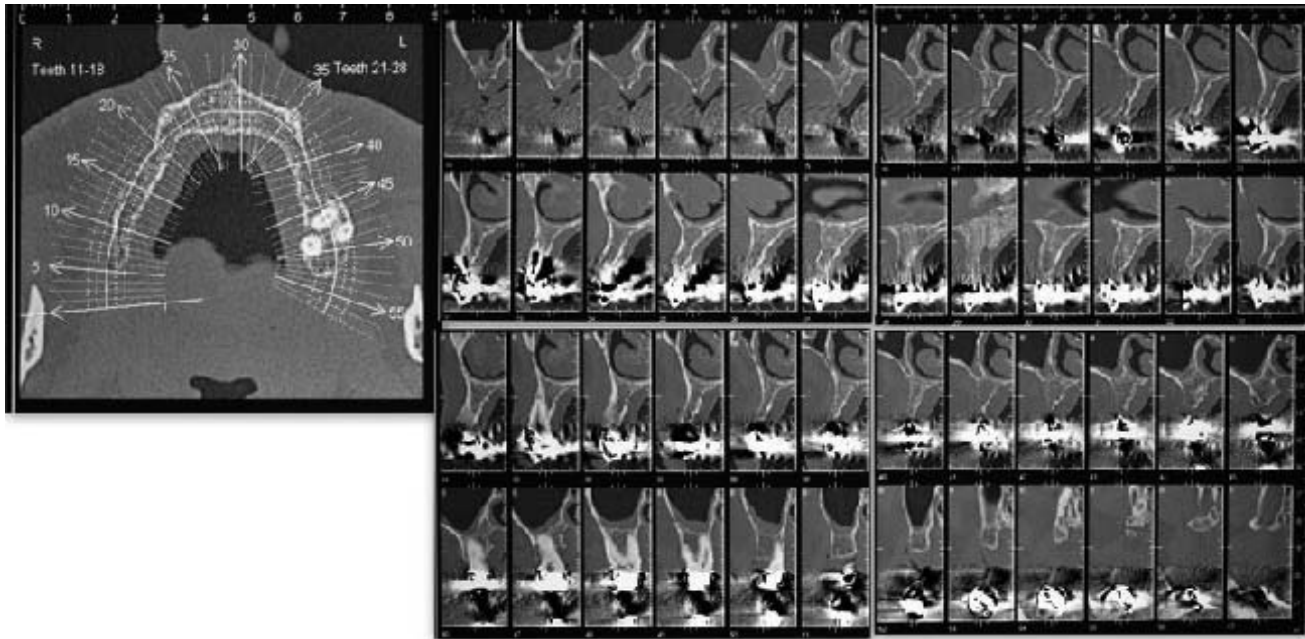


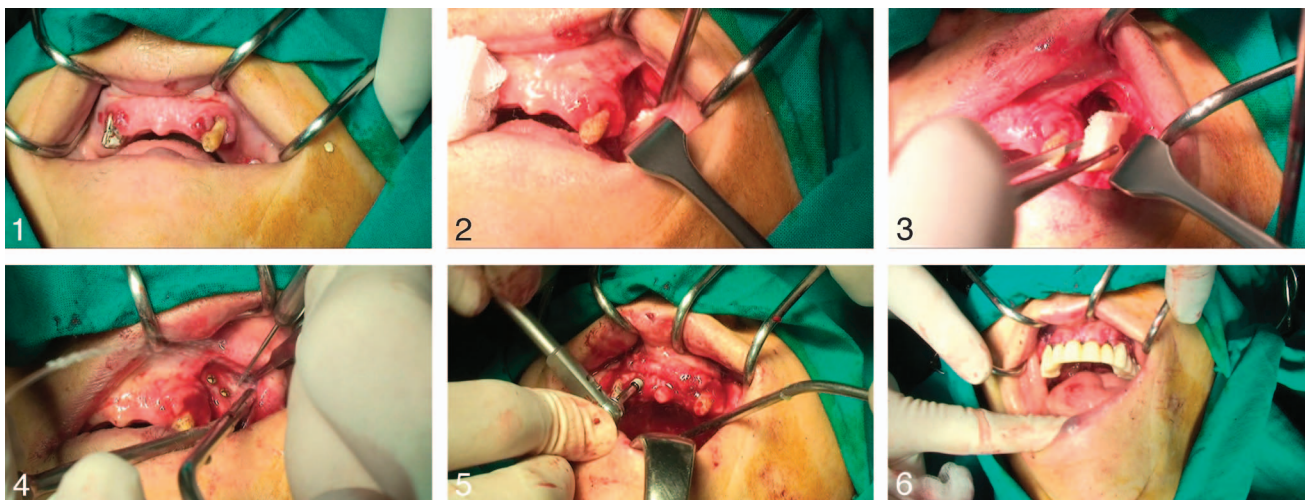
FIGURE 1. Computerized tomographic image showing severe horizontal atrophy.

After 5 months of healing, the computerized tomography follow-up and surgical re-entry were performed (Figure 8). After removal of the provisional prosthesis and infiltration of local anesthesia, mucoperiosteal flaps were raised to expose both grafted areas. The grafted areas showed minimal bone resorption: the bone was still at the level of the top of the microscrews, which were removed. The bleeding during the removal of the screws supported the successful integration of the graft.

After a slight osteoplasty to give right conformation to the ridge, measurements were taken showing a horizontal gain between 2 and 4 mm. Three implants were placed per side—

the same type used for the frontal region (4×11.5 mm). No immediate prosthetical load was realized, and the provisional prosthesis was again cemented on the remaining teeth.

After a 4-month healing period, the implants were uncovered and healing abutments were placed. The four remaining teeth were extracted and a removable provisional prosthesis was provided for use over the 2-week soft-tissue healing period. Afterward, a full arch resin restoration was loaded on the implants for 1 month, followed by a definitive metal ceramic prosthesis. The 16-month follow-up showed no marginal bone loss and no bone resorption, as well as soft-tissue stability on the grafted areas.



FIGURES 2–7. **FIGURE 2.** Clinical case of patient with severe bone atrophy. **FIGURE 3.** A minimally invasive approach with a single incision realizing instead of a mucoperiosteal tunnel. **FIGURE 4.** Positioning of tissue bank ilium bicortical bone (fresh frozen bone). **FIGURE 5.** Complete fixation of the block with three microscrews. **FIGURE 6.** Positioning of 2 submerged implants in the frontal region. **FIGURE 7.** Fixed provisional prosthesis.

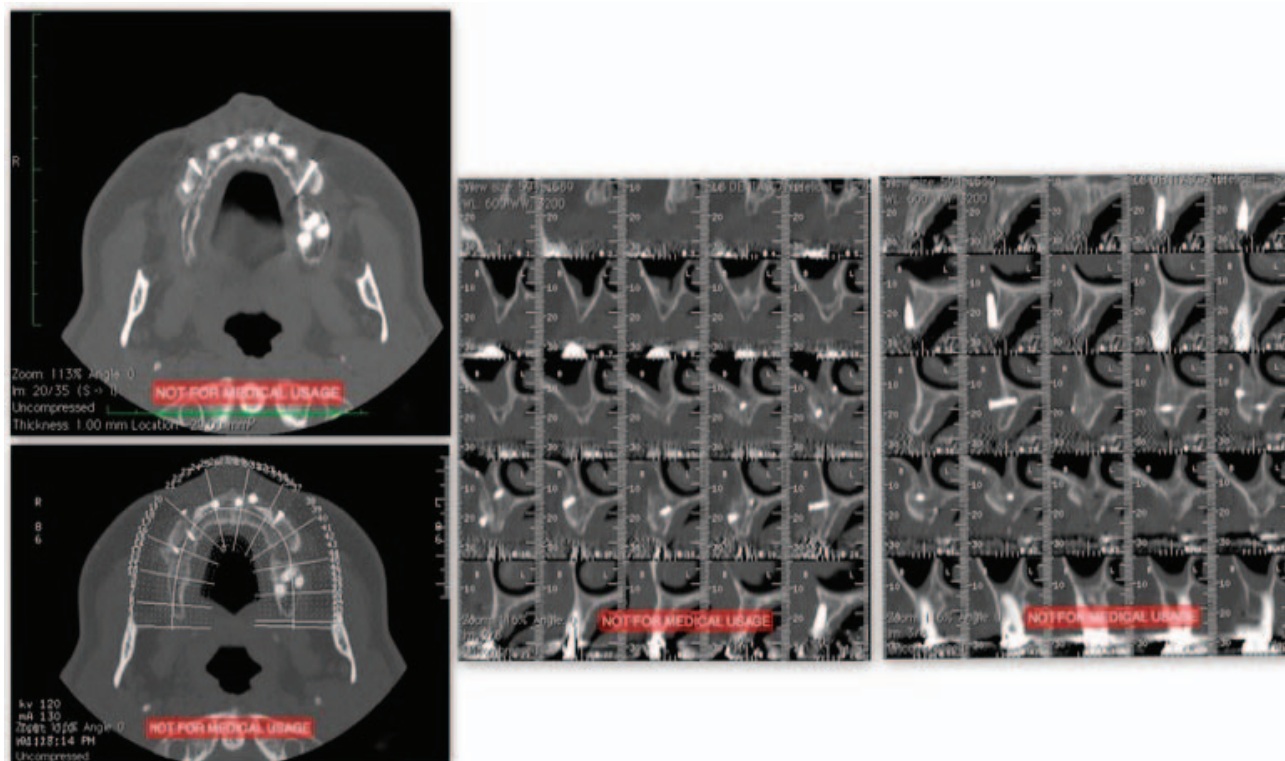


FIGURE 8. Computerized tomographic image at the 5-month follow-up.

DISCUSSION

Barone et al⁸ established success criteria for a bone graft: the absence of exposure and infection of the graft in the postoperative period, incorporation of the graft to the receptor bed, absence of radiolucent areas, bleeding of the grafted bone when the fixation screws are removed, and achievement of adequate volume and density to place the dental implants. In the case presented here these criteria were all satisfied.

The tunnel technique provided primary intention closure of the surgical wound, thereby avoiding dehiscences and infections, and reducing the edema and the postoperative discomfort for the patient. Dehiscences are reported to be among the most frequent complications associated with bone grafting, so preventing them can result in a higher predictability of the graft.^{3,11,12}

Clinical and histologic studies support the use of FFB,^{6,10,13} and it has been suggested that the results of a graft with homologous and autologous bone are comparable, even though the healing phase is more critical and longer for the allograft.¹⁴ The FFB is believed to have both osteoconductive properties—thanks to its solid structure and medullary spaces that allow blood vessel infiltration bone ingrowth—and osteoinductive action; freezing does not affect the bone morphogenetic proteins contained in the bone.¹⁵ In addition, polymerase chain reaction serologic tests on the donor tissue ensure the safety of the graft: viral infection transmission is believed to be the main potential disadvantage of allografts,^{16,17} although to date, however, no such occurrences have been reported in the dental literature. The risk of viral transmission by unprocessed deep-frozen, nonirradiated grafts

from screened donors is currently less than 1:200 000 for hepatitis C virus and 1:1 million for human immunodeficiency virus. Such a risk is virtually nonexistent for processed bone grafts.

Homologous bone from tissue banks offers obvious advantages such as: readily available source of large volumes of material, extremely low antigenic potential, unblemished safety record in dentistry, and, of course, the absence of a donor-site surgery for the patient and its risk of surgical complications.^{7,18}

Use of PRF can also increase the predictability of bone foundation. Osteoblasts show high affinity for PRF membranes,¹⁹ and the constant release of growth factors guides the healing and remodeling of connective tissues.^{20,21} Dohan Ehrenfest et al have demonstrated that PRF, through a constant release of growth factors, is twice as effective at enhancing soft tissue healing, stimulating blood vessels ingrowth, cellular migration, and differentiation into bone-forming cellular lines.²² Furthermore, the presence of cytokines lowers the risk of infection within the graft by controlling inflammation.²³

Although there is no evidence that a delayed placement in the grafted areas is more predictable, the data obtained so far,^{24,25} and the use of allograft that proved to have a longer and more critical healing phase²⁶ were the reasons why we chose delayed placement.

For the same reason, delayed prosthetic loading was chosen, even though primary stability of the implants was good. The possibility of using a provisional fixed prosthesis balanced the choice of a longer therapy.

CONCLUSIONS

When the surgical protocol is accurate and no complications occur during the healing phase, homologous bone grafting is a valid alternative to autograftings. The obvious advantage of this technique is sparing the patient a donor-site surgery. Utilization of homologous grafts with the tunnel technique reduces surgical trauma, postoperative discomfort, and the risk of exposure and failure of the graft during the healing phase. Use of PRF to cover the graft can enhance bone formation and soft-tissue healing.

In our experience, onlay grafting with frozen bone is a predictable technique for horizontal augmentation. In the case of a vertical augmentation, however, our advice is grafting with a sandwich interpositional technique.

ABBREVIATIONS

FFB: fresh frozen bone

PRF: platelet-rich fibrin

REFERENCES

- McAllister BS, Haghghat K. Bone augmentation techniques. *J Periodontol*. 2007;78:377–396.
- Borgonovo AE, Marchetti A, Vavassori V, Censi R, Boninsegna R, Re D. Treatment of the atrophic upper jaw: rehabilitation of two complex cases. *Case Rep Dent*. 2013;2013:154795.
- Hasson O. Augmentation of deficient lateral alveolar ridge using the subperiosteal tunneling dissection approach. *Oral Surg Oral Med Oral Pathol Oral Radiol Endod*. 2007;103:e14–e19.
- Maestre-Ferrín L, Boronat-López A, Peñarrocha-Diago M, Peñarrocha-Diago M. Augmentation procedures for deficient edentulous ridges, using onlay autologous grafts: an update. *Med Oral Patol Oral Cir Bucal*. 2009;14:e402–e407.
- de Macedo LG, de Macedo NL, do Socorro Ferreira Monteiro A. Fresh-frozen human bone graft for repair of defect after adenomatoid odontogenic tumour removal. *Cell Tissue Bank*. 2009;10:221–226.
- Khan SN, Cammisa FP Jr, Sandhu HS, Diwan AD, Girardi FP, Lane JM. The biology of bone grafting. *J Am Acad Orthop Surg*. 2005;13:77–86.
- Carinci F, Brunelli G, Zollino I, et al. Mandibles grafted with fresh-frozen bone: an evaluation of implant outcome. *Implant Dent*. 2009;18:86–95.
- Barone A, Covani U. Maxillary alveolar ridge reconstruction with nonvascularized autogenous block bone: clinical results. *J Oral Maxillofac Surg*. 2007;65:2039–2046.
- Quattlebaum SB, Mellonig JT, Hansel NF. Antigenicity of freeze-dried cortical bone allograft in human periodontal osseous defects. *J Periodontol*. 1988;59:394–397.
- Keith JD Jr, Petrungraro P, Leonetti JA, et al. Clinical and histologic evaluation of a mineralized block allograft: results from the developmental period (2001–2004). *Int J Periodontics Restorative Dent*. 2006;26:321–327.
- Mellonig JT. Autogenous and allogeneic bone grafts in periodontal therapy. *Crit Rev Oral Biol Med*. 1992;3:333–352.
- Gomes KU, Carlini JL, Biron C, Rapoport A, Dedivitis RA. Use of allogeneic bone graft in maxillary reconstruction for installation of dental implants. *J Oral Maxillofac Surg*. 2008;66:2335–2338.
- Köndell PA, Mattsson T, Astrand P. Immunological responses to maxillary on-lay allogeneic bone grafts. *Clin Oral Implants Res*. 1996;7:373–377.
- Heard RH, Mellonig JT. Regenerative materials: an overview. *Alpha Omegan*. 2000;93:51–58.
- Perrott DH, Smith RA, Kaban LB. The use of fresh frozen allogeneic bone for maxillary and mandibular reconstruction. *Int J Oral Maxillofac Surg*. 1992. 21:260–265.
- Buck BE, Resnick L, Shah SM, Malinin TI. Human immunodeficiency virus cultured from bone. Implications for transplantation. *Clin Orthop Relat Res*. 1990;251:249–253.
- Mellonig JT. Donor selection, testing, and inactivation of the HIV virus in freeze-dried bone allografts. *Pract Periodontics Aesthet Dent*. 1995;7:13–22.
- Morelli T, Neiva R, Wang HL. Human histology of allogeneic block grafts for alveolar ridge augmentation: case report. *Int J Periodontics Restorative Dent*. 2009;29:649–656.
- Gassling V, Hedderich J, Açil Y, Purcz N, Wiltfang J, Douglas T. Comparison of platelet rich fibrin and collagen as osteoblast-seeded scaffolds for bone tissue engineering applications. *Clin Oral Implants Res*. 2013;24:320–328.
- Dohan DM, Choukroun J, Diss A, et al. Platelet-rich fibrin (PRF): a second-generation platelet concentrate. Part III: leucocyte activation: a new feature for platelet concentrates? *Oral Surg Oral Med Oral Pathol Oral Radiol Endod*. 2006;101:e51–e55.
- Choukroun J, Simonpieri A, Del Corso M, Mazor Z, Sammartino G, Dohan Ehrenfest DM. Controlling systematic perioperative anaerobic contamination during sinus-lift procedures by using metronidazole: an innovative approach. *Implant Dent*. 2008;17:257–270.
- Dohan Ehrenfest DM, de Peppo GM, Doglioli P, Sammartino G. Slow release of growth factors and thrombospondin-1 in Choukroun's platelet-rich fibrin (PRF): a gold standard to achieve for all surgical platelet concentrates technologies. *Growth Factors*. 2009;27:63–69.
- Choukroun J, Diss A, Simonpieri A, et al. Platelet-rich fibrin (PRF): a second-generation platelet concentrate. Part IV: clinical effects on tissue healing. *Oral Surg Oral Med Oral Pathol Oral Radiol Endod*. 2006;101:e56–e60.
- Clementini M, Morlupi A, Agrestini C, Barlattani A. Immediate versus delayed positioning of dental implants in guided bone regeneration or onlay graft regenerated areas: a systematic review. *Int J Oral Maxillofac Surg*. 2013;42:643–650.
- Peñarrocha-Diago M, Aloy-Prósper A, Peñarrocha-Oltra D, Guirado JL, Peñarrocha-Diago M. Localized lateral alveolar ridge augmentation with block bone grafts: simultaneous versus delayed implant placement: a clinical and radiographic retrospective study. *Int J Oral Maxillofac Implants*. 2013;28:846–853.
- Mulliken JB, Glowacki J, Kaban LB, Folkman J, Murray JE. Use of demineralized allogeneic bone implants for the correction of maxillofacial deformities. *Ann Surg*. 1981;194:366–372.

Queries for orim-42-01-04

This manuscript/text has been typeset from the submitted material. Please check this proof carefully to make sure there have been no font conversion errors or inadvertent formatting errors. Allen Press.