

Early treatment of eyelid lymphedema

Fabrizio Schonauer · Simone La Padula · Guido Molea

Received: 20 December 2009 / Accepted: 23 June 2011
© Springer-Verlag 2011

Introduction

Lymphedema of the eyelids is a very annoying condition which causes functional and aesthetic problems. Appearance of the eyelids can condition the individual's self-image, and some pathological alteration of this anatomical area can often have psychological and social consequences. Eyelid lymphedema can recur even after entirely satisfactory surgical treatment.

We present a case of early stage bilateral lymphedema of the lower eyelid, in a renal transplant patient, treated by an early approach.

Case report

A 53-year-old male patient presented to our clinic with bilateral lower eyelid lymphedema of an early stage. He was affected by polycystic kidney disease and received a renal transplant in 2006 followed by sirolimus and steroid-based therapy. Eight months post-transplantation, he developed a bilateral swelling of the lower eyelid (Fig. 1). At the time of presentation, the swelling interfered with the patient's normal eye closure. On examination, the patient had localized edema with a *peau d'orange* appearance. There was no evidence of systemic edema. It was decided to treat the patient in two stages. First, he underwent syringe aspiration of the fluid component followed by application of compressive dressings. At the second stage, 3 months later, the remaining excess skin

was removed from the lower eyelids using a direct approach at the infraorbital crease level. Histology showed diffuse corion edema associated with vascular and lymphatic ectasiae and confirmed the diagnosis of localized lymphedema (Fig. 2). At 2 years follow-up, no sign of recurrence was present on either lower eyelids. The result was functionally and cosmetically satisfactory to the patient with well-healed scars (Fig. 3).

Discussion

Lymphedema is a chronic disease which can cause significant morbidity. It is characterized by regional accumulation of excessive amounts of interstitial protein-rich fluid (early stage lymphedema), as a result of an imbalance between the demand for lymphatic flow and the capacity of the lymphatic circulation. Chronic lymph stasis produces an increase in the number of fibroblasts, adipocytes, and keratinocytes in the edematous tissues. Mononuclear cells (chiefly macrophages) often demarcate the chronic inflammatory response. Ultimately, these processes lead to progressive subcutaneous fibrosis (advanced stage lymphedema).

Primary lymphedema is a condition with no identifiable antecedent cause that can be present at birth (congenital), at puberty (praecox), or more rarely, in adulthood (tarda). Secondary lymphedema results from various types of damage to the lymphatic vessels; this may be radiation therapy, surgery, infections, drugs, or other clinical conditions [1]. An association of generalized lymphedema with sirolimus therapy after a renal transplant has also been described [2].

Although the etiology of localized lymphedema is sometimes unknown, there are some cases associated

F. Schonauer · S. La Padula (✉) · G. Molea
AOU Federico II, Via Pansini,
Naples, Italy
e-mail: simonelp83@hotmail.it

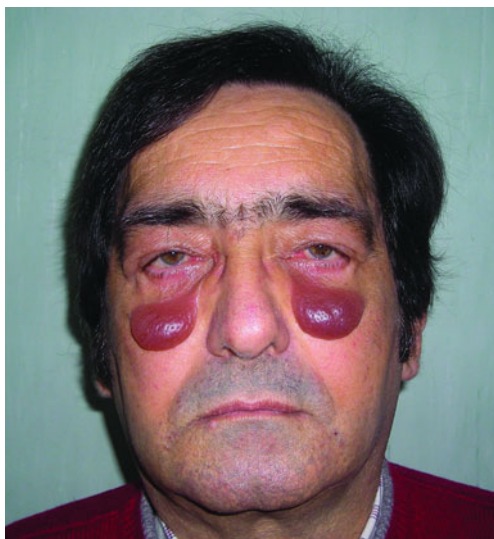

Fig. 1 Preoperative appearance of bilateral lower eyelid early stage lymphedema

with other clinical conditions such as acne rosacea and neurofibromatosis [3, 4]. A combination of lymph stasis-promoting factors such as trauma, obesity, infections, and inflammatory disorders produces localized lymphedema. In the case of eyelid lymphedema, acne rosacea is one of the most common associated conditions [3–5].

Some reports dealing with the surgical treatment of eyelid lymphedema have been published, most of them on an advanced stage of the condition. James [6] reported three cases of bilateral eyelid lymphedema treated by excision of the edematous skin and subcutaneous tissue and skin grafting. In 1979, Clodius [7] reported a case of a recurrent lymphedema of the right upper eyelid, treated by excision and split-skin grafting. Maisels and Korachi [8] successfully treated a case of bilateral periorbital edema in a

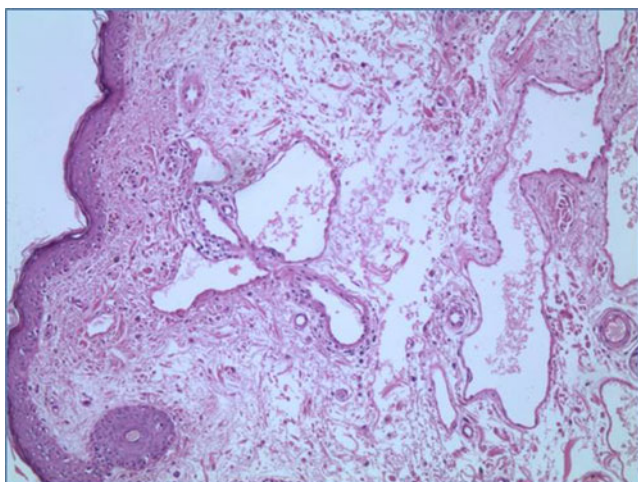


Fig. 2 Histology revealed dilated lymphatic channels and diffuse corion edema

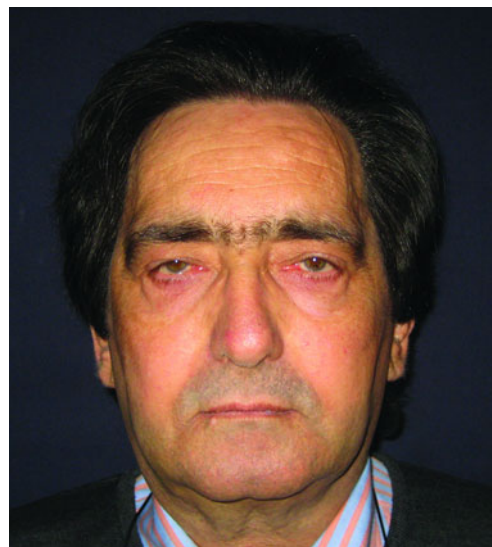

Fig. 3 Postoperative aspect after staged correction showing a satisfactory result with well-healed scars

patient with the yellow nail syndrome, by excision of the lower eyelid's skin and split-skin grafting. In 2002, Kabir et al. [9] reported a case of upper and lower eyelid bilateral lymphedema treated by staged debulking without skin grafting. This resulted in poor aesthetic results.

We advocate, where possible, early diagnosis and treatment of eyelid lymphedema, at a stage with no subcutaneous fibrosis. This can avoid the use of skin grafts, reduce the risk of recurrence, and lead to better functional and aesthetic results.

References

1. Rockson SG (2001) Lymphedema. *Am J Med* 110(4):288–295
2. Al-Otaibi T, Ahamed N, Nampoory MR, Al-Kandari N, Nair P, Hallm MA, Said T, Samhan M, Al-Mousawi M (2007) Lymphedema: an unusual complication of sirolimus therapy. *Transplant Proc* 39(4):1207–1210
3. Lu S, Tran TA, Jones DM, Meyer DR, Ross JS, Fisher HA, Carlson JA (2009) Localized lymphedema (elephantiasis): a case series and review of the literature. *J Cutan Pathol* 36(1):1–20, Epub 2008 Jun 17
4. Lai TF, Leibovitch I, James C, Huilgol SC, Selva D (2004) Rosacea lymphoedema of the eyelid. *Acta Ophthalmol Scand* 82(6):765–767
5. Bernardini FP, Kersten RC, Khouri LM, Moin M, Kulwin DR, Mutasim DF (2000) Chronic eyelid lymphedema and acne rosacea. Report of two cases. *Ophthalmology* 107(12):2220–2223
6. James JH (1978) Lymphedema of the eyelids. *Plast Reconstr Surg* 61(5):703–706
7. Clodius L (1979) Lymphedema of the eyelids. *Plast Reconstr Surg* 63(1):115
8. Maisels DO, Korachi AOA (1985) Lymphoedema of the eyelids in the yellow nail syndrome. *Br J Plast Surg* 38(1):93–96
9. Kabir SM, Raurell A, Ramakrishnan V (2002) Lymphoedema of the eyelids. *Br J Plast Surg* 55(2):153–154